

This article was downloaded by: [Trelles, Mario]

On: 8 July 2009

Access details: Access Details: [subscription number 912959599]

Publisher Informa Healthcare

Informa Ltd Registered in England and Wales Registered Number: 1072954 Registered office: Mortimer House, 37-41 Mortimer Street, London W1T 3JH, UK



Journal of Dermatological Treatment

Publication details, including instructions for authors and subscription information:

<http://www.informaworld.com/smpp/title~content=t713889756>

Hair structures are effectively altered during 810 nm diode laser hair epilation at low fluences

Mario A. Trelles ^a; Fernando Urdiales ^b; Marwan Al-Zarouni ^a

^a Vilafortuny Medical Centre, Dubai, UAE ^b Instituto Medico Miramar, Malaga, Spain

First Published:2009

To cite this Article Trelles, Mario A., Urdiales, Fernando and Al-Zarouni, Marwan(2009)'Hair structures are effectively altered during 810 nm diode laser hair epilation at low fluences',Journal of Dermatological Treatment,99999:1,

To link to this Article: DOI: 10.1080/09546630903085286

URL: <http://dx.doi.org/10.1080/09546630903085286>

PLEASE SCROLL DOWN FOR ARTICLE

Full terms and conditions of use: <http://www.informaworld.com/terms-and-conditions-of-access.pdf>

This article may be used for research, teaching and private study purposes. Any substantial or systematic reproduction, re-distribution, re-selling, loan or sub-licensing, systematic supply or distribution in any form to anyone is expressly forbidden.

The publisher does not give any warranty express or implied or make any representation that the contents will be complete or accurate or up to date. The accuracy of any instructions, formulae and drug doses should be independently verified with primary sources. The publisher shall not be liable for any loss, actions, claims, proceedings, demand or costs or damages whatsoever or howsoever caused arising directly or indirectly in connection with or arising out of the use of this material.

SHORT REPORT

Hair structures are effectively altered during 810 nm diode laser hair epilation at low fluences

MARIO A. TRELLES¹, FERNÁNDO URDIALES² & MARWAN AL-ZAROUNI¹

¹Vilafortuny Medical Centre, Dubai, UAE, ²Instituto Médico Miramar, Malaga, Spain

Abstract

Background: Diode lasers with high fluence and cooling technology are effective at removing unwanted hair but are also associated with discomfort and morbidity, especially when treating dark or tanned skins. **Methods:** Thirty patients with skin phototypes IV and V (range: 23–62 years of age; average: 39 years) underwent a single hair removal treatment using a new diode laser (810 nm) technology that incorporates low fluence but very high average power. The treatment technique employed multiple, in-motion, repetitive laser passes on a 100 cm² area of the skin. A 5 mm punch biopsy was carried out before and after a single treatment. Tissue samples were harvested and stained with haematoxylin-eosin. **Results:** The physical integrity of hair follicles was altered with inflammatory infiltrate, hair shaft detachment from its sheath, and perifollicular oedema, related to incipient necrosis. **Conclusion:** Low fluence but high average power diode laser technology yields significant changes in hair structure and architecture in patients with dark skin types. The procedure caused low levels of discomfort and was well tolerated.

Key words: Fluences, hair removal, histology, laser, melanin

Introduction

Photo-epilation was the most practised medical intervention in 2008 (1). Unwanted hair causes psychological distress due to 'imposed' social rules. Several techniques that use different light devices can be used to remove hair, but there are limitations when treating dark or tanned skins.

When laser epilation is carried out on light skin and dark hair, the rate of success is high (2). The selective absorption of laser light by the hair follicle in the 810–1200 nm spectrum band is expected to cause thermal damage to the hair follicle growth centres—bulge, bulb and papilla. Reports based on histology observations present extensive immediate damage of hair follicles after laser treatment (0–8). Reports on low fluence epilation with IPL devices (9), filterless flash-lamp systems (10), and the alexandrite laser (11) produce partial degeneration of hair follicles and changes such as coagulation in the standard pattern of the neighbouring tissue. Thus, there is a need for an

improved method for hair removal which heats the hair follicles to a sufficient temperature for hair removal while delivering a minimal amount of thermal energy to the epidermis (to achieve minimal discomfort).

A new 810 nm diode laser device for hair removal may have clinical advantages for epilation on dark and/or tanned skins due to its very high average power, high repetition rate, albeit at low a fluence, and may be a safer procedure that offers the possibility of achieving high clearance rates of hair removal with low morbidity. In order to evaluate the extent of treatment effects at the level of the hair follicle and to assess the extension of these effects in tissue, we have examined the histology of epilated areas in 30 patients immediately after a single treatment session.

Materials and methods

Patients with phototypes IV and V (15 males and 15 females in each group), ranging from 23 to 62 years

Correspondence: Mario A. Trelles, Instituto Medico Vilafortuny / ANTONI DE GIMBERNAT FOUNDATION, Av. Vilafortuny, 31, E-43850, Cambrils, Spain. Fax: 34 977 791024. E-mail: imv@laser-spain.com

(Received 10 March 2009; accepted 18 May 2009)

ISSN 0954-6634 print/ISSN 1471-1753 online © 2009 Informa UK Ltd.
DOI: 10.1080/09546630903085286

of age (average 39 years), were enrolled. No patient had undergone any previous photo-epilation and all had dark, thick hair that they regularly epilated using either electric or blade razors.

The study was approved by the Ethics Committees of the Antoni de Gimbernat Foundation.

Patients underwent a single hair removal treatment with the 810 nm Soprano[®] XL diode laser device (Alma Lasers, Caesarea, Israel). The nozzle of the laser hand-piece incorporates Sapphire Dual Chill Window Technology through which a coolant is in constant circulation. Also, the hand-piece has an adapter to connect a cold air tube that focuses directly where the nozzle is pointed and continuously cools the area of treatment. The window from which the laser emits is 12 × 10 mm in size. The cooling system (Cryo 5; Zimmer ElektroMedizin, Neu-Ulm, Germany) was set to operate at intensity level #5 (high flow of cold air).

The diode laser pulses at a fixed rate of 10 Hz and at fluences varying from 5 to 10 J/cm². Lower fluences can be used in darker skin types; 8 J/cm² was used in this study. The pulse width adapts according to selected fluences, and ranges from 10 ms for 5 J/cm² to 20 ms for 10 J/cm². The treatment technique involves moving the hand-piece in a sweeping constant movement. The skin surface for treatment was divided into 10 × 10 cm squares and each received a total of 8 kJ. Thus, each 1 cm² of skin received on average 80 J/cm² (8000 J/100 cm² = 80 J/cm²). The reason for dividing the treatment area into 100 cm² areas was to provide homogenous treatment exposure and to carry out systematic epilation. The hand-piece was moved over the skin at a speed of approximately 10 cm per second.

Areas of epilation were four side burns, 12 axillae, four bikini lines, six legs and four arms. Treatment areas were shaved and thoroughly cleansed with soap and water. Then, a thin coat of gel at an ambient temperature was applied to the skin surface for the purpose of facilitating the sliding of the laser nozzle over the skin at the time of treatment. During treatment, tissue temperature progressively increased. The end point for stopping laser passes was when intense erythema, pain or a burning sensation was present or when an accumulative energy of 8 kJ was attained. Patients were told to expect a heat sensation and were asked to advise the therapist when they felt unbearable pain or an intolerable heat sensation. The purpose of the treatment was not to burn the skin but only to reach levels of tolerable pain or intolerable heat sensation. In order to have a reference of the temperature achieved, skin temperature was measured during treatment with an infra-red (IR) surface thermometer (IR Surface Thermometer A28886; Zenit Measuring/Testing Instruments[™], USA). At the time of treatment, the

temperature never exceeded 42°C. Presumably, due to the high average power and depth of penetration of the 810 nm diode, the tissue temperature in the dermis was higher, as well as at the level of the hair follicle, due to its significant higher density in melanin content acting as a chromophore conductor for the 810 nm laser emission. Once patients felt minor pain and/or a heat sensation (12), the hand-piece was moved to the neighbouring area, continuing the epilation procedure.

Once total fluence was achieved in the whole area of treatment, a 5 mm punch biopsy was carried out in the same manner as it was performed prior to the start of treatment. A local injection of 0.5 ml of lidocaine, without vasoconstrictor, was administered. Samples were processed and stained with haematoxylin-eosin and were examined by an independent pathologist, who was requested to comparatively evaluate the changes occurring before and after treatment.

Results

The post-treatment epidermis was of normal configuration, and the keratin layer was intact with no identifiable changes. The samples of seven patients had some epidermal-dermal junction contraction, represented by more noticeable papillary crests in the dermis together with cytopathic and vacuole changes at the keratinocyte level (Figure 1). Moderate oedema, particularly in the dermis, was visible in its superficial layer. The dermis appeared normal and viable. Hair shafts detached from hair sheaths with perifollicular oedema, related to incipient necrosis, clearly visible due to the darker colour of the staining. There were variations in the standard physical integrity of hair follicles with inflammatory infiltration. None of these changes were present in the pre-treatment samples (Figures 2 and 3). Perifollicular oedema was clearly visible in all samples, together with signs of haemorrhage between the collagen fibres located at stroma level, representing a trauma which could be responsible for the epilation effect. Low-fluence laser epilation caused anatomical changes in the follicle that compromised its integrity.

Discussion

Safety and efficacy standards are not well established for laser hair removal in patients with a dark skin type. Methods to destroy hair follicles while keeping the epidermis alive are needed. We found that an 810 nm diode laser delivering a very high average power at a low fluence altered hair structure. While the changes were not dramatic, clinically there were fewer and finer hairs in the treated areas. **Patients reported delayed regrowth at follow-up 1 month after treatment.** A

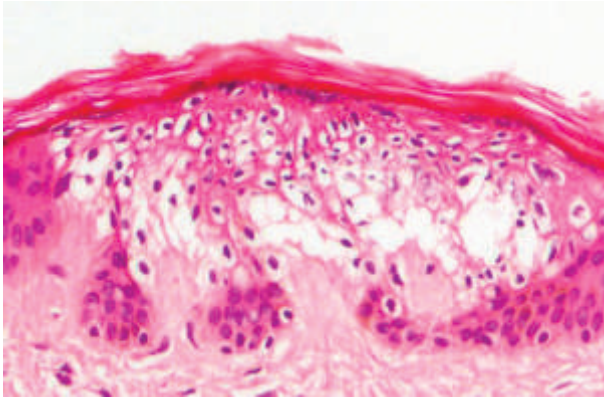


Figure 1. Skin $\times 125$ H&E. Cytopathic and vacuole changes at the keratinocyte level are clearly seen.

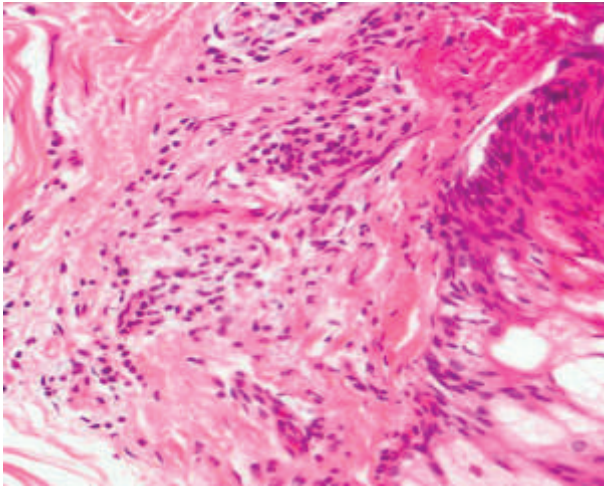


Figure 2. Skin $\times 400$ H&E. Perifollicular oedema and peribulb thermal damage, represented by darker staining, and polymorphic nuclear cell inflammatory infiltration are noticed respecting the integrity of the neighbouring tissue.

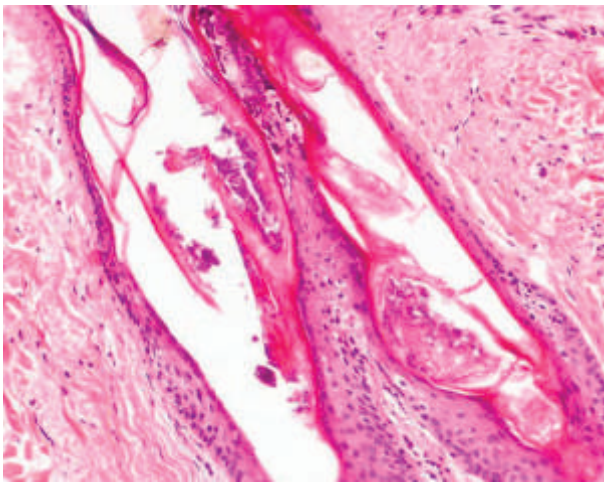


Figure 3. Skin $\times 250$ H&E. Images of haemorrhaging are seen in between the collagen fibres at the stroma hair level.

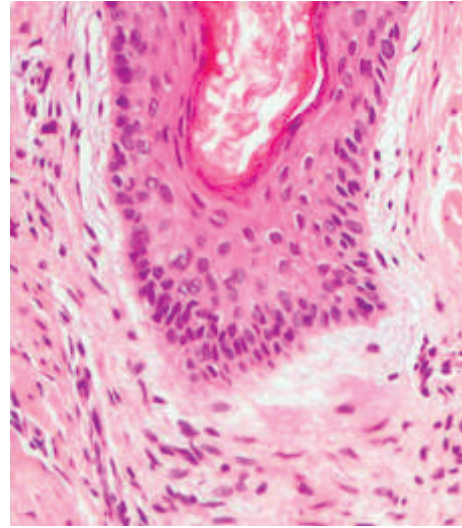


Figure 4. Skin $\times 400$ H&E. Perifollicular oedema is clearly noticed as a consequence of thermal effects.

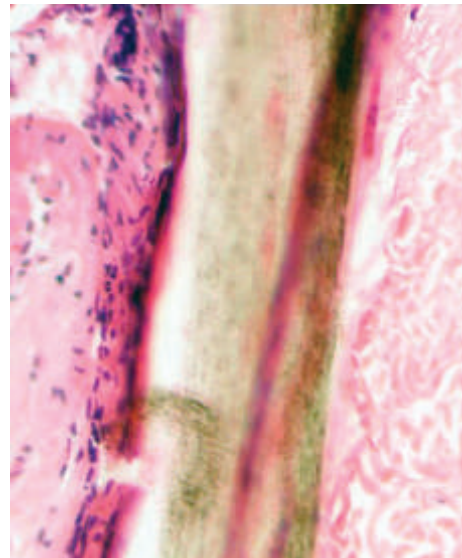


Figure 5. Skin $\times 400$ H&E. Presence of hair disruption with detachment from its shaft. Peri-isthmic fibrosis is observed together with inflammatory infiltration.

single session with the low-fluence, high pulse rate, 810 nm treatment can produce effective epilation.

Although the fluence of each individual pulse delivered is relatively low, the rapidly delivered pulses collectively effectively heat the patient's dermis. Since the hair follicle is in thermal equilibrium with the surrounding tissue and it is more sensitive to heat, it is more prone to thermal damage with repetitive, prolonged laser exposure. Thus, once the sub-dermal layer is significantly heated and the temperature at the hair follicle is sufficiently high, only a few additional high-rate pulses of low fluence are needed to raise the temperature

of the hair follicle to an effective temperature to impair the function of its biological elements. More-over, melanin in the hair follicle acts as a chromophore, providing a degree of selective heating. Because an excessive heat gradient may cause pain, once the sub-dermal layer is sufficiently heated, individual pulses should only provide enough energy to the hair follicle to achieve a critical temperature to impair the function of biological elements and hair growth.

Some follicles were damaged in their outer root sheath, others appeared with lesions of the inner root sheath, and others were of normal aspect. This may be attributed to a different volume and degree of heat in contact with the target, which is translated into oedema (Figure 4). Also, heat propagation from dermis to epidermis may be responsible for cytoplasm changes and vacuole formation at the level of keratinocytes, as observed in practically all 'immediately after' samples (Figure 5).

The 810 nm diode laser causes significant thermal damage and histological alterations to the hair follicle but not to the epidermis, even in patients with dark skin types. This may have important clinical implications for the dark-skinned population seeking a safe and effective hair removal procedure.

Acknowledgements

The author declares no financial or other interest in the companies and/or equipment mentioned in this study.

The preliminary conclusions of this study are registered in the academic activities of the FUNDACION ANTONI DE GIMBERNAT year 2000–2008.

References

1. Kronemyer, Bob, Associate Editor American Society for Aesthetic Plastic Surgery. ASAPs Statistics report. Slight Rise in Cosmetic Procedures. The Aesthetic Guide May/June 2008, www.miinews.com
2. Ort RJ, Dierickx C. Laser hair removal. *Semin Cutan Med Surg.* 2002;21:120–44.
3. Ort RJ, Anderson RR. Optical hair removal. *Semin Cutan Med Surg.* 1999;18:140–58.
4. Price ML, Griffiths WA. Normal body hair – A review. *Clin Exp Dermatol.* 1985;10:80–97.
5. Lin TY, Manuskiatti W, Dierickx CC, Farinelli WA, Fisher ME, Flotte T, et al. Hair growth cycle affects hair follicle destruction by ruby laser pulses. *J Invest Dermatol.* 1998;111:100–13.
6. Ross EV, Ladin Z, Kreindel M, Dierickx C. Theoretical considerations in laser hair removal. *Dermatol Clin.* 1999;17:330–55.
7. Sadick NS, Weis RA, Shea CR, Nagel H, Nicholson J, Prieto VG. Long term photoepilation using a broad-spectrum intense pulsed light source. *Arch Dermatol.* 2000;136:1330–40.
8. Dierickx CC, Grossman MC, Farinelli WA, Anderson RR. Permanent hair removal by normal-mode ruby laser. *Arch Dermatol.* 1998;134:830–42.
9. Roosen GF, Westgate GE, Philpott M, Beretty PJM, Nuijs T, Bjerling P. Temporary hair removal by low fluence photoepilation: Histological study based on biopsies and cultured human hair follicles. *Lasers Surg Med.* 2008;40:520–8.
10. Trelles MA, Allones I, Calderhead RG, Velez M. Hair removal evaluated with a filterless flashlamp-based system: A preliminary study in 10 patients. *J Cosmet Laser Ther.* 2003;5:10–24.
11. Drosner M, Stangel S, Hertenberger B, Klimek H, Pettke-Rank C. Low dose epilation by alexandrite laser: A dose response study. *med Laser Appl.* 2001;16,4:293–98.
12. Yovanny Ferrer Lozano. Dolor nociceptivo. *Conceptos actuales. Revista Electrónica de PortalesMedicos.com.* Accessed electronically. www.portalesmedicos.com/publicaciones/articles/824/1/Dolor-nociceptivo-conceptos-actuales.html. Published Nov. 26, 2007, Vol II, no 18;388.