

A Clinical and Biological Evaluation of a Novel, Noninvasive Radiofrequency Device for the Long-Term Reduction of Adipose Tissue

Sylvie Boisnic, MD,^{1,2} Marc Divaris, MD,² Andrew A. Nelson, MD,³ Nima M. Gharavi, MD, PhD,⁴ and Gary P. Lask, MD^{4*}

¹Institution GREDECO, Paris, France

²Department of Plastic and Maxillo-Facial Surgery, University Pitie Salpetriere, Paris, France

³Department of Dermatology, Tufts University, Boston, Massachusetts

⁴Department of Dermatology, University of California, Los Angeles, California

Background and Objective: A novel, noninvasive technology, utilizing suction-coupled radiofrequency (RF) heating and ultra-short pulse duration, high-voltage electrical pulses was studied for its efficacy and safety on adipose tissue reduction.

Methods: Twenty-one subjects underwent treatment of their abdominal fat once weekly for 6 weeks. Clinical outcomes including abdominal circumference, adipose tissue thickness (measured by ultrasound), adipose tissue weight, body weight, and clinical photographs were obtained at visits 1 and 3 months after last treatment. Adverse events were recorded. Three subjects, who were undergoing a future elective abdominoplasty, were treated with the same protocol, but on only one side of the abdomen before abdominoplasty. Biopsies from the RF-treated and untreated sides were harvested during abdominoplasty and cultured; measurements of adipocyte size and shape, rate of apoptosis, collagen production, and dermal thickness were determined.

Results: Significant clinical improvements ($P < 0.05$) were observed for the following clinical outcomes: reduction of abdominal circumference (113.4–110.7 cm), reduction of subcutaneous adipose tissue thickness (40.5–38.5 mm), and reduction in adipose tissue weight (32.2–30.7 kg) at 3-month follow-up visits. Overall patient weight also decreased, which was statistically significant at 1-month follow-up, but was not statistically significant at 3-month follow-up (73.9–73.3 kg, $P = 0.609$). Histologically, adipocytes were observed to have decreased size and withered shape, with increased levels of apoptosis; increased collagen synthesis, with compaction and reorganization of the dermis was also observed. Only minor, transient side effects were reported.

Conclusions: This novel, noninvasive RF device was effective for improving subcutaneous fat, reducing abdominal circumference and reducing subcutaneous fat layer thickness. Histologically, these improvements appear to be partly related to increased adipocyte apoptosis. *Lasers Surg. Med.* 46:94–103, 2014.

© 2014 Wiley Periodicals, Inc.

Key words: radiofrequency; adipose tissue; circumference reduction; noninvasive fat destruction; apoptosis; irreversible electroporation; neocollagenosis

INTRODUCTION AND OBJECTIVE

Adipocytes store energy in the form of cytosolic triglycerides. These fat cells make up adipose tissue in the body and are held together by an organized lobular network of collagenous fibrous septae. Adipocytes can distend dramatically with increased triglyceride content. Excess adipose tissue can lead to aesthetically displeasing body contour bulges and convex distensions. Fat lobules are contained within and partitioned by fibrotic septal divisions running perpendicular and oblique to the surface of the skin. In females, these partitions can weaken and the orientation of the septae be altered, resulting in focal herniations of fat into the dermis, creating the classic bulging skin nodules of cellulite [1]. Suction-assisted Lipoplasty (SAL) performed under tumescent anesthesia has long been the gold standard treatment to reduce focal fat excess [2]. Recently, ultrasound, laser, and radiofrequency (RF) technologies have been added to traditional lipoplasty, resulting in energy-based liposuction, to improve the soft tissue contraction, and minimize ecchymosis

Conflict of Interest Disclosures: All authors have completed and submitted the ICMJE Form for Disclosure of Potential Conflicts of Interest and have disclosed the following: S.B.: A BodyFX device was provided for her use during this study; no other disclosures. M.D.: No relevant disclosures. A.A.N.: Received speaking honoraria from InMode, Inc. and has stock options with InMode, Inc. N.M.G.: No relevant disclosures. G.P.L.: Received speaking honoraria from InMode, Inc. and has stock options with InMode, Inc.

*Correspondence to: Gary P. Lask, MD, Department of Dermatology, University of California Los Angeles, 200 UCLA Medical Plaza, Suite 450, Los Angeles, CA 90095.

E-mail: glask@mednet.ucla.edu

Accepted 23 December 2013

Published online in Wiley Online Library

(wileyonlinelibrary.com).

DOI 10.1002/lsm.22223

and edema compared with traditional SAL [3–9]. While effective, these energy-based liposuction technologies still require an invasive lipoplasty procedure. In the last few years, there has been a dramatic increase in demand for noninvasive procedures for fat sculpting and reduction. The ideal noninvasive fat treatment would safely and effectively “destroy or deactivate” fat cells nonsurgically for long term, noninvasive body contour improvements. This has led to the development and popularization of noninvasive technologies based on suction-massage, high-intensity focused ultrasound (HIFU), cryolipolysis, low-level lasers, and RF [10]. To date, however, these devices have resulted in only modest improvement of adipose tissue. Additionally, current technologies do not simultaneously enhance the quality, elasticity, or contraction of the dermis to tighten the treatment area, which is an ideal goal for noninvasive body sculpting.

Radiofrequency devices have several important characteristics that may make them an ideal choice for noninvasive fat treatment and body sculpting. RF devices utilize electrical conductance, in the form of rapidly alternating electrical current (at various frequencies and voltages) to cause oscillation of cellular structures that are in the electrical path, thereby increasing intermolecular motion. As the current alternatively flows, molecular collisions increase thereby creating thermal energy (heat). RF technology therefore utilizes the resistance (impedance) of the tissue itself to generate heat rather than directly transferring heat. Adipocytes have high tissue resistance, which allows them to generate significant heat when RF energy is passed through the tissue. Additionally, adipocytes have relatively low heat transfer coefficients, which means they do not transmit significant amounts of the heat to unintended surrounding structures. As a result of these characteristics, RF energy can be used to generate substantial heating of adipocytes while limiting the spread of this heat to surrounding structures, resulting in localized adipocyte thermolysis. RF heating has also been shown to improve dermal collagen, elastin, and ground substance leading to skin tightening, which is important in achieving an optimal body contour result using noninvasive adipose reduction technology [11].

The objective of the study was to evaluate both clinically and histologically, the efficacy, safety, and mechanism of action of a novel RF device (BodyFX, InMode Inc, Yokneam, Israel). The device utilizes two types of RF: (1) initial basic RF pulses in the standard 1 MHz range, and (2) ultra-short pulse duration, high-amplitude, high-voltage RF pulses. The basic RF pulses precisely and uniformly heats the dermal and hypodermal tissue, resulting in collagen stimulation and skin tightening [10,11]. The second RF (ultra-short pulse duration, high-amplitude, high-voltage RF pulses), selectively targets the cell membrane of adipocytes with an irreversible electroporation (IRE) effect. IRE alters the adipocyte cell membrane potential, impairing the ability of the cell to maintain its internal pH. This disrupts the continuity of the adipocyte cell membrane, impairs the adipocyte’s ability to regulate cell homeostasis, and ultimately should cause the adipo-

cyte to undergo apoptosis. The combination of these two RF treatments should allow for more effective treatment of subcutaneous adipocytes, tightening of the skin in the treatment area, and ultimately improved clinical outcomes.

MATERIALS AND METHODS

The Device

The BodyFX device (InMode, Inc., Yokneam, Israel) utilizes a suction-coupled, bipolar RF configuration, with a built-in infrared skin surface temperature sensor (Fig. 1). A vacuum draws the tissue up between the bipolar RF electrodes, facilitating a deep dermal and fat layer treatment. The triple action system works by suction-coupled, even heating of the skin and adipose tissue to a uniform depth of 2.5 cm.

The deep heating results in increased adipocyte temperature and metabolic activity leading to a nondestructive reduction in adipocyte cell volume [10,11]. As the dermis is being heated, collagen remodeling and tightening occurs, similar to effects seen with traditional noninvasive RF skin tightening technologies [11]. The device allows for the user to determine the RF power level, as well as a preset cut off dermal/adipocyte temperature. In order to achieve and maintain the skin temperature, the device hand piece incorporates several sensors, including: high and low impedance sensors, a contact sensor, and an epidermal thermal sensor. The device measures skin temperature, impedance, and epidermal contact 10 times per second allowing for real time feedback and a uniform, safe treatment. The device deploys a software algorithm that immediately, automatically, and temporarily terminates the delivery of RF energy to the area once the preselected cut off temperature is reached. Once the temperature of this treatment area drops to 0.1°C below the set target temperature, or as the physician moves the treatment applicator over a new area that has not yet reached the predetermined temperature, the device automatically reactivates the RF energy. This on-going, automated temperature modulation allows the temperature and

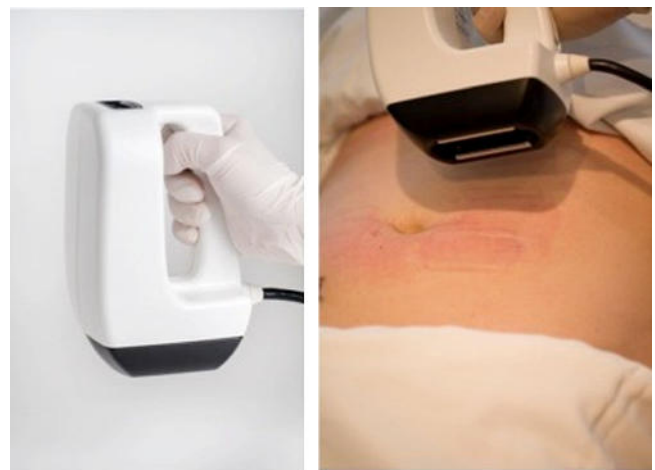

Fig. 1. The BodyFX applicator.

duration of adipose tissue exposure to be carefully controlled by the user, facilitating a safe and effective treatment at a therapeutic thermal endpoint.

When the preset dermal and adipose therapeutic end point is reached, typically set at a range between 41 and 43°C, the device then begins to emit trains of high-amplitude, high-voltage, ultra-short (nanosecond) pulse duration RF pulses into the preheated adipose tissue. The intensity of these ultra-short pulse duration RF pulses is controlled and set by the user. The RF is triggered repeatedly once the preset cut off temperature is reached, and as long as that temperature is maintained, trains of high voltage, ultra-short pulse duration RF (second RF) are emitted. These high-voltage, ultra-short pulse duration RF pulses selectively target the cell membrane of adipocytes, resulting in an IRE effect. IRE disrupts the continuity of the adipocyte cell membrane, hindering its ability to regulate cell homeostasis. Once the continuity of the cell membrane is irreversibly disrupted, this starts the cascade of apoptosis, ultimately resulting in permanent, programmed cell death of the adipocytes [11,12].

Subjects

Twenty-four subjects between the age of 31 and 59 (average age of 44.7 years), exhibiting clinical indications of a local excess of adipose tissue were selected and included in the study. Three of these patients were scheduled to undergo an elective abdominoplasty, at the completion of the study. Subjects were asked to maintain their usual diet and exercise routine so that the device could be evaluated free from the influence of other variables.

Only subjects of appropriate age and no adverse medical conditions were included in the study. Subjects were excluded from participation if they had gained or lost weight in the previous three months. General contraindications included pacemakers, pregnancy and nursing, epilepsy, thyroid dysfunction, diabetes, cardiac arrhythmias, heart disease or uncontrolled hypertension, history of cancer (5 years of remission), liver or kidney disease, medical conditions causing immunosuppression, use of isotretinoin (Accutane[®]) within the previous 6 months, or any other skin disorders or condition such as abnormal wound healing. Diuretics and anti-coagulants were also banned during the study. All participants in the study signed an Informed Consent Form.

Experimental Procedure

Twenty-four subjects were treated with six weekly sessions with the device. All patients were treated in France in the clinic of two authors (SB and MD). Twenty-one subjects were treated on the full abdomen and each patient served as their own control for clinical assessment immediately following the completion of RF treatments, as well as 1- and 3-month follow-up visits. The remaining three subjects were scheduled (at their request) for an abdominoplasty procedure immediately following the completion of the series of treatments. These patients

were treated on the right side of the abdomen only, while the contralateral untreated side served as a control; these three subjects provided tissue samples for histologic analysis following their abdominoplasty procedures. Since abdominoplasty was scheduled immediately following the RF treatment series, 1- or 3-month clinical follow-up data were not obtained and only their histologic results were included in this study. However, as discussed below, the biopsies were harvested in a validated survival medium up to 14 days, which has been shown to be the equivalent to 6–8 weeks *in vivo* [13–21].

Subjects were bound to prescribed conditions related to their eating habits 2 hours before and after each session and were specifically asked to avoid heavy meals, fasting, carbonated drinks, coffee, or tea. The subjects' abdomen was prepped clean before the start of the treatment and the vacuum chamber of the device was prepped and disinfected with bleach pads following each session.

Treatment parameters were set at 40 W and 42°C, representing the RF power and the skin surface cut off temperature, respectively. The basic RF pulse duration was set at 3–3.5 seconds. The high amplitude, high voltage, ultra-short pulse duration “second RF” was set at a level as high as the subject could tolerate, typically ranging from 5 to 10 (correlating to the number of trains of RF pulses emitted). The surface of the abdomen was divided into two zones, right and left, with each zone approximately the size of 6–8 vacuum chambers. Treatments were performed by applying the device applicator for the entire pulse duration (3–3.5 seconds) and then moving to the tissue immediately adjacent with an overlap of the electrode footprint of 20%. Each zone was treated in a clockwise fashion until that zone reached the cut-off temperature (42°C). Once the cut-off temperature was attained, usually in about 60 seconds, the second RF was then automatically emitted in the treatment zone. The cut off temperature was maintained in the treatment zone for 5 minutes with a minimum of 10 passes of high-voltage second RF pulse treatments, resulting in 5 minutes of high amplitude RF pulse treatments. The process was repeated on the other side of the abdomen. A second treatment pass of both zones was then performed, resulting in a total tissue treatment time of 10 minutes for each zone. The three abdominoplasty subjects, treated on one side only (one treatment zone), underwent their initial 5-minute treatment pass, then had a 5-minute rest period, and underwent a second 5-minute treatment pass. The number of zones treated per subject depended on the surface area of the person's abdomen with greater treatment zones necessary for very large patients. Total energies ranging from 8.5 to 29 kJ was used per session per subject on the full abdomen.

Clinical Assessments

The precise circumference of the treatment area before and after treatment sessions was measured. A tape measure was used to record circumference on a standing patient, based on a fixed vertical perpendicular measurement taken from the end of the tape measure at the level of

the floor; furthermore, the tape measure was kept in constant contact with the abdomen along the entire circumference. While there are always limitations with circumferential measurements, this method allows for a reproducible method of measurement. These assessments were performed on day 0 (prior to the first treatment), immediately following the completion of the series of six weekly treatments, and 1 and 3 months after the final treatment session.

A Tefal[®] BodySignal2 digital weight scale (REF: BM3100A9/26A-3810 R) was used to determine both the weight of the fat tissue (kg) of the subjects, as well as their overall weight (kg). Jewelry and clothing, except for undergarments, were removed for the weight measurements. These assessments were performed on day 0 (prior to the first treatment), immediately following the completion of the series of six weekly treatments, and 1 and 3 months after the final treatment session.

Photographs were taken in standardized conditions in exhalation before each treatment session in order to document the appearance of each subject. These assessments were performed on day 0 (prior to the first treatment), immediately following the completion of the series of six weekly treatments, and 1 and 3 months after the final treatment session.

Fat thickness was measured by ultrasound (Philips HD 11 XE) on noncompressible fat, measuring the abdominal fat layer thickness 5 cm inferior to the umbilicus. Ultrasound measurements were performed by a single technician, utilizing uniform pressure on the ultrasound transducer over noncompressible fat. While there are inherent limitations in ultrasound measurement of fat layer due to compression, this method limits this potential variability. These measurements were performed before beginning the series of treatments, and 1 month after completing the treatment series. The initial examination was completed within 48 hours preceding the first measurements and treatment session.

Cellular and Histologic Assessments

Three patients were scheduled to undergo elective abdominoplasty at the completion of the treatment series as described above. Soft tissue composite skin and adipose biopsies were taken from the treated and untreated abdominal regions of these three subjects, and the specimens were maintained as next described. Histologic patient samples were cut into 3 cm² full-thickness pieces, with an initial depth of 2.5 cm. The histologic studies performed immediately after the abdominoplasty included the full tissue depth, with a depth to 2.5 cm of adipose tissue analyzed.

Following the initial harvesting and analysis, the specimens were then maintained following a validated method of tissue culture, which permits the survival of normal skin and adipose tissue in *ex vivo* conditions to keep skin and adipose samples in survival condition [13–21]. This alternative culture method avoids testing *in vivo* biopsy specimens and maintains the model in a validated

near *in vivo* metabolic condition. The elapsed time for the procedure is artificially accelerated three to four times that of the normal time needed *in vivo* [15]. Thus, samples analyzed after 14 days correspond to *in vivo* changes seen 6–8 weeks following the completion of the treatment. The histologic patient samples were maintained in 3 cm² full-thickness pieces, and were thinned to a depth of 3 mm of subcutaneous fat to facilitate tissue culture; as a result, in the accelerated tissue culture results, the analysis was based on observation of the superficial adipocytes (up to 3 mm of adipose tissue depth maintained in culture). The culture specimens were initially washed three times with an antibiotic solution (300 U/ml penicillin and 300 µg/ml streptomycin). Skin biopsies were placed with the epithelium uppermost, at an air/liquid interface, on culture inserts (filter pore size 12 µm). These inserts were set on six-well plates and culture medium was added underneath three times a week. Medium was Dulbecco's minimal essential medium (DMEM) containing antibiotics (100 U/ml penicillin and 100 µg/ml streptomycin), 200 µg/ml L-glutamine, bovine pituitary extract, growth factors, and fetal calf serum. All supplements were freshly made with each medium change every two days and applied at the epidermal level. Skin biopsies were then put in a humidified atmosphere of 95% air–5% CO₂ at 37°C. These skin cultures were then used as the basis for histologic and immunohistochemistry studies.

Treated and untreated skin cultures were then compared at day 0 (day of abdominoplasty), day 3, and day 14. At each of these time points, a portion of the soft tissue specimen was analyzed for traditional histopathology and morphometric assessment; a comparison was conducted between the treated and untreated abdominal skin, consisting of an analysis of adipocyte architecture and function, as well as an evaluation of the appearance and thickness of the hypodermis (measured in microgram at 100× magnification). Photography was used to visualize any alterations between treated and untreated areas.

At days 0, 3, and 14, a portion of the skin culture was also analyzed with immunohistochemistry. A rabbit polyclonal antibody directed against human apoptosis protease activating factor 1 (APAF-1) (Spring Bioscience, IgG, 1/300 dilution) was used. The immune-detection was made with an indirect technique of immunoperoxidase in four levels, amplified (kit CsA II, DAKO, Les Ulis, France) and stained in red by 3-amino-9-ethylcarbazole (AEC). Greater levels of expression of APAF-1 indicate greater apoptotic activity in the cells.

After 14 days of culture, the remaining soft tissue specimen was utilized for analyzing collagen synthesis using a validated collagen assay [13–17]. Skin samples were enzymatically digested in an acetic acid 0.5 M solution containing pepsin overnight at 4°C. The fibroblastic activity for collagen synthesis was evaluated by a spectrophotometric method (540 nm) measuring the acid-soluble new collagen synthesized after a specific fixation by Sirius red staining (Sircoll Collagen Assay, Interchim, Montlucon, France). The results were expressed in microgram of collagen per mg protein.

Statistical Analyses

Means, standard deviations (SD), and 95% confidence interval (CI) for each characteristic were reported. Due to the substantial variability of the patient's baseline characteristics as a result of great variety in patient's body types, SD for each measurement vary greatly. However, since each patient served as a paired baseline and outcome measurement, Paired Sample *T* tests could be utilized to determine the statistical significance of any improvement. Paired Sample *T* tests were used to assess changes in baseline (day 0) and follow-up measures (immediately after six treatment sessions, 1-month follow-up, and 3-month follow-up) for abdominal circumference, fat tissue thickness, fat tissue weight, and body weight. All analyses were conducted using IBM SPSS 21.0 and significance was set at an α of 0.05.

RESULTS

Clinical Findings

Circumferential measurement. Summary results of the circumference (cm) of subject's abdomen are expressed in Table I. The average circumference of subjects ($n = 21$) treated on the abdomen decreased significantly from 113.4 cm (SD = 15.3) pretreatment to 111.5 cm (SD = 15.0) following the sixth treatment session with the device, indicating a statistically significant improvement (Paired Samples *T*-test $t(20) = 6.99$, $P < 0.001$). This clinical improvement was maintained in the follow-up period. One month after completing the series of treatments, the

abdominal circumference decreased further from the baseline of 113.4 (SD = 15.3) to 111.1 cm (SD = 14.5), a statistically significant improvement (Paired Sample *T*-test, $t(20) = 5.73$, $P < 0.001$). **At 3 months follow-up, the average abdominal circumference decreased even further to 110.7 cm (SD = 14.5), for a total reduction of 2.7 cm from baseline.** Again, this decrease was statistically significant, with a Paired Sample *T*-test, $t(20) = 5.84$, $P < 0.001$. Photography allowed for a comparison between pretreatment and follow-up 3 months after completing the series of treatments (Figs. 2 and 3). **Significant improvement in the appearance of subcutaneous fat, as well as skin tightening, was directly observed in these photographs.**

Echography. Summary results of the fat thickness (mm) of subject's target zone, as measured by ultrasound, are expressed in Table I comparing subcutaneous fat layer thickness at baseline prior to treatment and 1 month after completing the series of treatments. The measurement of subcutaneous fat thickness showed a significant reduction from an average of 40.5 mm (SD = 11.4) at baseline to an average of 38.5 mm (SD = 11.0) 1 month following the series of treatments, representing a statistically significant reduction (Paired Sample *T*-test, $t(20) = 5.88$, $P < 0.001$). **An echography example illustrating clinical improvement is shown in Figure 4 (patient 7), in which a reduction in the subcutaneous fat layer thickness from 37 to 31 mm was observed at one month following completion of the treatment series.**

Adipose tissue weight. Summary results of subject's bodily adipose tissue (kg) are expressed in Table I. The

TABLE I. Average Measurements of Abdominal Circumference, Fat Tissue Thickness, Fat Tissue Weight, and Body Weight Before Treatment, Immediately Following Six Treatment Sessions, At 1-Month Follow-Up, and at 3-Month Follow-Up Visits

	<i>N</i>	Abdominal circumference ^a (cm)	Fat tissue thickness ^b (mm)	Fat tissue weight ^c (kg)	Body weight ^d (kg)
Before treatment, mean \pm SD	21	113.4 \pm 15.3	40.5 \pm 11.4	32.2 \pm 8.9	73.9 \pm 12.4
After six sessions, mean \pm SD (95% CI)	21	111.5 \pm 15.0 (1.32–2.44), $P < 0.001$	N/A	31.2 \pm 8.4 (0.62–1.36), $P < 0.001$	73.0 \pm 11.8 (0.46–1.34), $P < 0.001$
One month follow-up, mean \pm SD (95% CI)	21	111.1 \pm 14.5 (1.45–3.12), $P < 0.001$	38.5 \pm 11.0 (1.32–2.77), $P < 0.001$	30.8 \pm 8.4 (1.02–1.92), $P < 0.001$	72.7 \pm 11.9 (0.68–1.67), $P < 0.001$
Three months follow-up, mean \pm SD (95% CI)	21	110.7 \pm 14.5 (1.78–3.75), $P < 0.001$	N/A	30.7 \pm 8.2 (0.85–2.20), $P < 0.001$	73.3 \pm 11.7 (–1.55–2.58), $P = 0.609$

95% Confidence Interval reported reflect changes between *before treatment* and each consecutive time points.

P values calculated using Paired Sample *T* tests

^aCircumferential measurements of the abdomen (cm) before treatment (day 0), immediately following six treatment sessions, 1 month, and 3 months after completing a series of six weekly noninvasive RF treatments.

^bMeasurement of subcutaneous fat layer thickness as assessed with ultrasound (mm) before treatment (day 0) and 1 month after completing a series of six weekly noninvasive RF treatments.

^cFat tissue weight (kg) measured with digital weight scale before treatment (day 0), immediately following six treatment sessions, 1 month, and 3 months after completing a series of six weekly noninvasive RF treatments.

^dOverall subject weight (kg) measured with digital weight scale before treatment (day 0), immediately following six treatment sessions, 1 month, and 3 months after completing a series of six weekly noninvasive RF treatments.

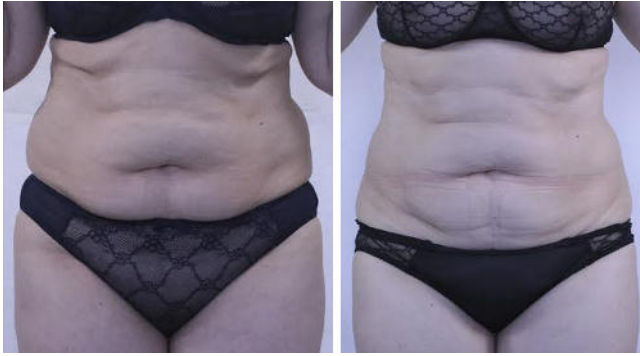

Fig. 2. Clinical improvement in appearance of abdominal subcutaneous fat following a series of six weekly noninvasive RF treatments. Before is shown on left, and 3 months following completion of series of treatments shown on right. Note the reduction in abdominal circumference, volume of subcutaneous fat, improved body contour, and tightening of skin in abdominal treatment area.

average weight of subjects' ($n = 21$) adipose tissue significantly decreased from 32.2 kg (SD = 8.9) pretreatment to 31.2 kg (SD = 8.4) at the immediate conclusion of the six treatment sessions (Paired Sample T -test, $t(20) = 5.65$, $P < 0.001$). One month following the completion of the series of treatments, the average adipose tissue weight further decreased to 30.8 kg (SD = 8.4) (Paired Sample T -test, $t(20) = 6.80$, $P < 0.001$). Three months following the completion of the series of treatments, the average weight of subjects' adipose tissue stayed stable at 30.7 kg (SD = 8.2) (Paired Sample T -test, $t(20) = 4.72$, $P < 0.001$), for a total average fat reduction of 1.5 kg.

Body weight. Summary results of the body weight (kg) for subjects are expressed in Table I. The average weight of subjects ($n = 21$) treated with the RF device, was noted to have decreased from 73.9 (SD = 12.4) to 73.0 (SD = 11.8) immediately following the completion of the series of 6 treatments (Paired Sample T -test, $t(20) = 4.31$, $P < 0.001$). One month after the completion of the series of treatments,

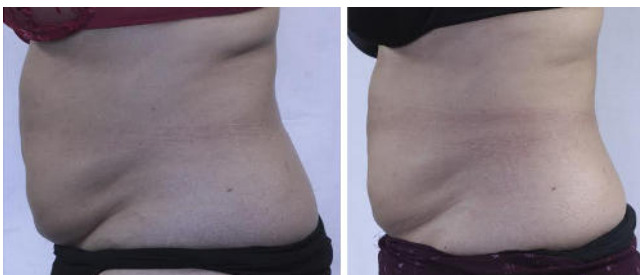


Fig. 3. Clinical improvement in appearance of abdominal subcutaneous fat following a series of six weekly noninvasive RF treatments. Before is shown on left, and 3 months following completion of series of treatments is shown on right. Note the reduction in abdominal circumference, volume of subcutaneous fat, improved body contour, and tightening of skin in abdominal treatment area.

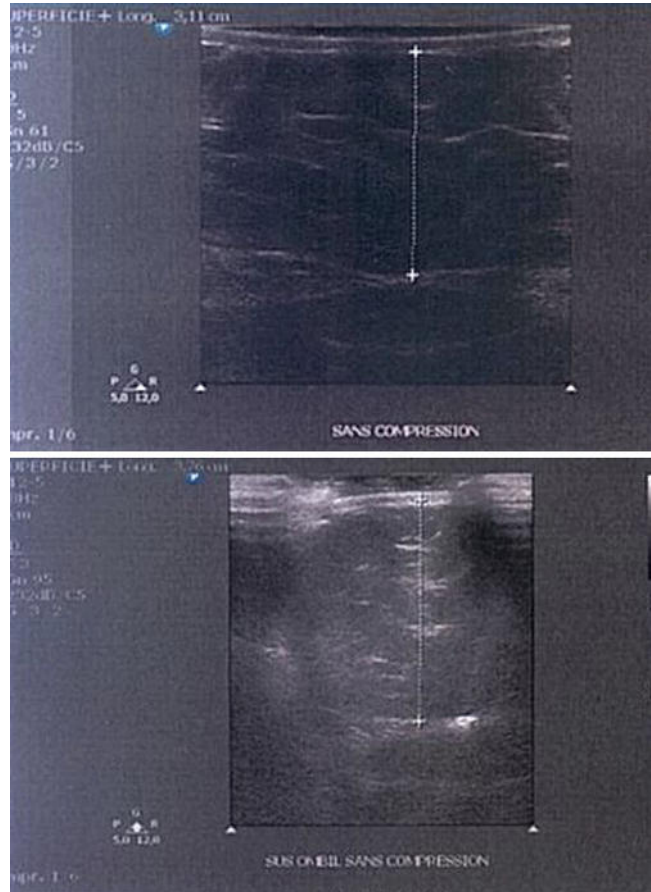


Fig. 4. Ultrasound assessment of subcutaneous fat thickness. This example demonstrates reduction in subcutaneous fat thickness from a thickness of 37 mm (before, shown as top image) to a thickness of 31 mm (after, shown as bottom image) 1 month following a series of six noninvasive RF treatments.

the average weight of subjects further decreased to 72.7 kg (SD = 11.9) (Paired Sample T -test, $t(20) = 4.99$, $P < 0.001$) and 3 months following the completion of the series of treatments, the average weight increased slightly to 73.3 kg (SD = 11.7); at the 3 month postprocedure visit, there was not a statistically significant change in overall patient weight (Paired Sample T -test, $t(20) = 0.52$, $P = 0.609$). In all cases at all measurement points, the total weight change for each subject was less than the reduction in their adipocyte weight.

Adverse events. Discomfort during the treatment was a rare occurrence with a report of a pinching feeling under the area of treatment, or a slight, "shock"-like sensation combined with surprise at the first discharge of the high amplitude, ultra-short pulsed RF. Transient and mild post treatment bruising infrequently occurred following treatment, likely related to the vacuum function of the device. Bloating, nausea, migraines, diarrhea, nerve spasms, stomach aches, and frequent urination were reported as rare side effects of the treatment but may represent epiphenomena.

Cellular and Histologic Findings

Histological evaluation of skin and adipose samples. After preparation and analysis of the skin samples from the three subjects, alteration of the fat cells was found in treated areas of the hypodermis to a depth of 2.5 cm in the initial histologic analysis. Control, nontreated skin, contained adipose tissue with normal round adipocytes; skin treated with the RF device showed altered adipocyte histology, with a reduction of fat cell size with flattening and/or elongation of the cells. Fat cell membranes in the RF-treated adipose appeared shrunken and withered; occasionally, the adipocyte cell walls were partially ruptured. No necrosis was observed, and there was no destruction of adjacent structures (epidermis, blood vessels, nerves or dermal collagen). These induced changes to the adipose architecture were noted immediately following the completion of the series of treatments (at the time of abdominoplasty). Furthermore, these changes

persisted and became more apparent in superficial adipose tissue at days 3 and 14 in accelerated culture (Fig. 5).

Immunostaining for adipocyte apoptosis. Within the adipose tissue of the treated areas, increased levels of adipocyte apoptosis were observed immediately following the treatment series, with approximately 20% of all adipocyte cells staining positive for APAF-1, a validated marker of apoptosis. In contrast, the control untreated skin only rarely had adipocytes undergoing apoptosis, with less than 1% of adipocytes staining positive for APAF-1. At day 14 of culture, fat cell apoptosis had further increased (~30% of adipocytes staining positive for APAF-1) within the RF-treated adipose tissue (Fig. 6).

Dermal thickness and neocollagenesis. A significant reduction in dermal thickness, with tighter, more compact collagen, and an apparent decreased spaced between the collagen fibers, was noted following the RF treatment series (Fig. 7). At day 0 the average dermal

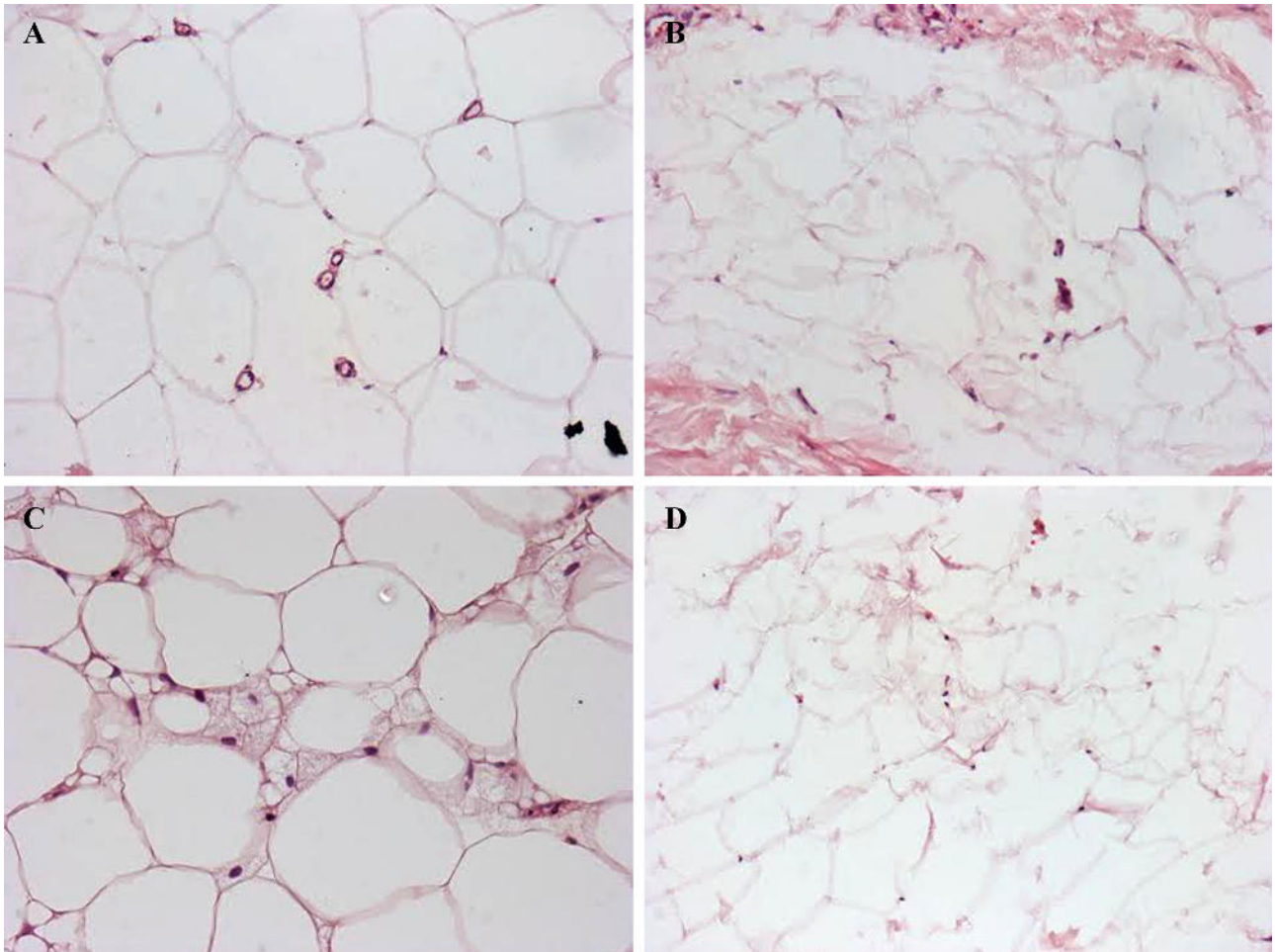


Fig. 5. Histologic findings. Tissue specimens, obtained during abdominoplasty, were cultured and processed for histologic analysis. Figures above (200 magnification) are from nontreated (control) skin (A,C), and skin treated with a series of six noninvasive RF treatments (B,D). In (A) and (B), the specimens were taken from culture immediately after completing the series of RF treatments. In (C) and (D), the specimens were obtained following tissue culture for 14 days. Note the round appearance of adipocytes in the untreated area, in contrast to the flattened, withered, and emptying appearance of the adipocytes from the RF-treated area. Figures above (200 \times magnification).

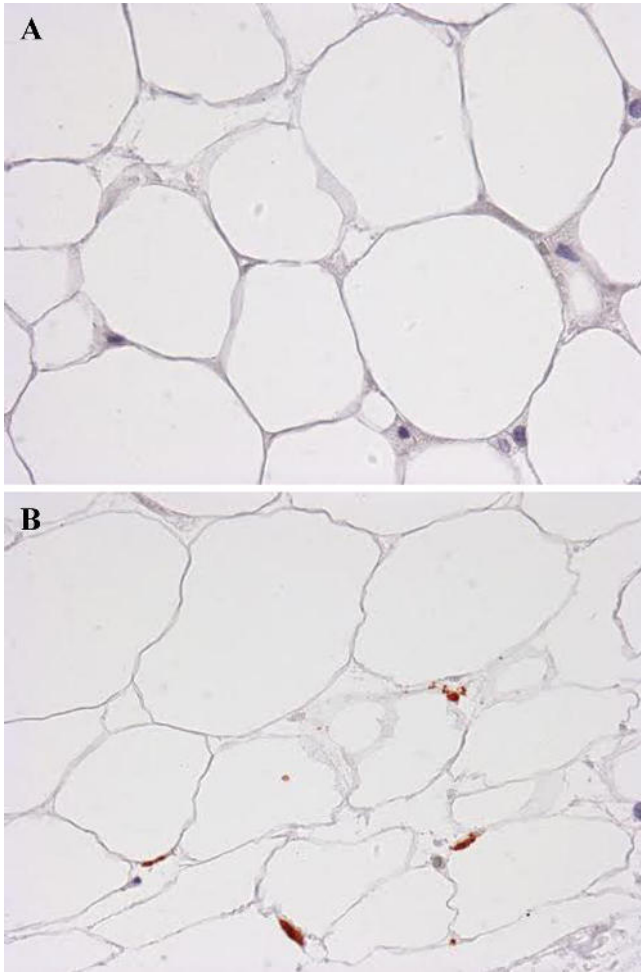


Fig. 6. Immunohistochemistry staining of APAF-1, a marker of apoptosis, after 14 days of tissue culture. **A:** Example of nontreated, control tissue (200 \times) showing low levels of staining for APAF-1. **B:** Example of tissue that underwent a series of six weekly RF treatments. Note the withered appearance of cell membranes, as well as the increased staining of APAF-1 in (B), indicating a higher level of adipocyte apoptosis. Control tissue (200 \times magnification).

thickness for the three subjects was 1,711.3 μm in the RF-treated zone versus 2,176.6 μm in the nontreated zone (measured at 40 \times magnification). At day 3, the average dermal thickness measured 1,463.3 μm in the RF-treated zone versus 1,965.3 μm in the nontreated zone. At day 14, the average dermal thickness had decreased to 1,452.8 μm in the RF-treated zone versus 1,646 μm in the nontreated zone, representing an average dermal compression of 193.2 μm . Additionally, a significant increase in collagen synthesis (neocollagenosis) was also observed after treatment by the RF device, with a mean collagen level of 57.6 $\mu\text{g}/\text{mg}$ in the treated zone versus 49.7 $\mu\text{g}/\text{mg}$ in the nontreated zone, as determined by the spectrophotometric method, representing an average increase of 13.7%.

DISCUSSION

Noninvasive fat reduction is a rapidly expanding field of cosmetic rejuvenation, as many patients are unwilling to

undergo the downtime and healing associated with traditional invasive suction lipoplasty or newer ultrasound and laser/RF assisted invasive lipoplasty procedures. To date, the clinical improvements associated with noninvasive fat reduction have been modest at best, may not address overlying skin laxity, and can be associated with pain or other adverse effects.

The RF device in this study appears to be a novel, safe, and effective method for noninvasive fat reduction as well as synchronous dermal enhancement and skin tightening. This study, incorporating 24 subjects, has permitted the visualization and quantification of the statistically significant reduction of abdominal fat after treatment by a novel RF device. Following a series of six weekly, noninvasive RF treatments, patients were observed to have a significant reduction in abdominal circumference, reduction in thickness of the subcutaneous fat layer as assessed by ultrasound, as well as a reduction in adipose tissue weight.

These improvements are noted immediately following the completion of the series of treatments, and persist with increased clinical efficacy observed 1 and 3 months after completing the series of treatments. There was a statistically significant decrease in patient weight initially following the series of treatments and at the 1-month follow-up visit; however, while there was still a decrease in overall patient weight at the 3-month follow-up visit, this decrease was not statistically significant. It is notable that while there was not a statistically significant reduction in overall patient weight at the 3-month follow-up point, there was still a maintained statistically significant reduction in adipose tissue weight at the 3-month follow-up visit, suggesting increased specificity of the device for fat. Clinical photographs demonstrated and correlated with this substantial clinical improvement following the series of treatments.

Ex vivo human skin cultures following the completion of the series of RF treatments showed a profound effect on subcutaneous adipocytes. The adipocyte cells were noted to have altered morphology, and increased expression of the apoptosis marker, APAF-1, suggesting that IRE induced apoptosis is the mechanism of action. Adipocyte apoptosis results in the release of triglycerides from the disintegrated cell membranes, but in a delayed and gradual manner, enabling a slow and safe removal through the interstitial space, and subsequent lipid transport systems, lymphatics and other metabolic functions. There was no evidence of necrosis or inflammatory changes noted in the adipocytes following treatments with this novel RF device. While IRE has been shown to be effective at inducing cellular apoptosis in other tissues, to our knowledge, this is the first documentation of IRE in adipose tissue with RF treatments [22–31].

In addition to the effect on adipocytes, this device was also noted to have an effect on dermal collagen. As the dermis was heated, the thickness of the collagen was noted to decrease indicating more compact, tighter dermal matrix. Furthermore, increased levels of collagen synthesis were observed following the completion of the series of RF treatments. This neocollagenosis and remodeled

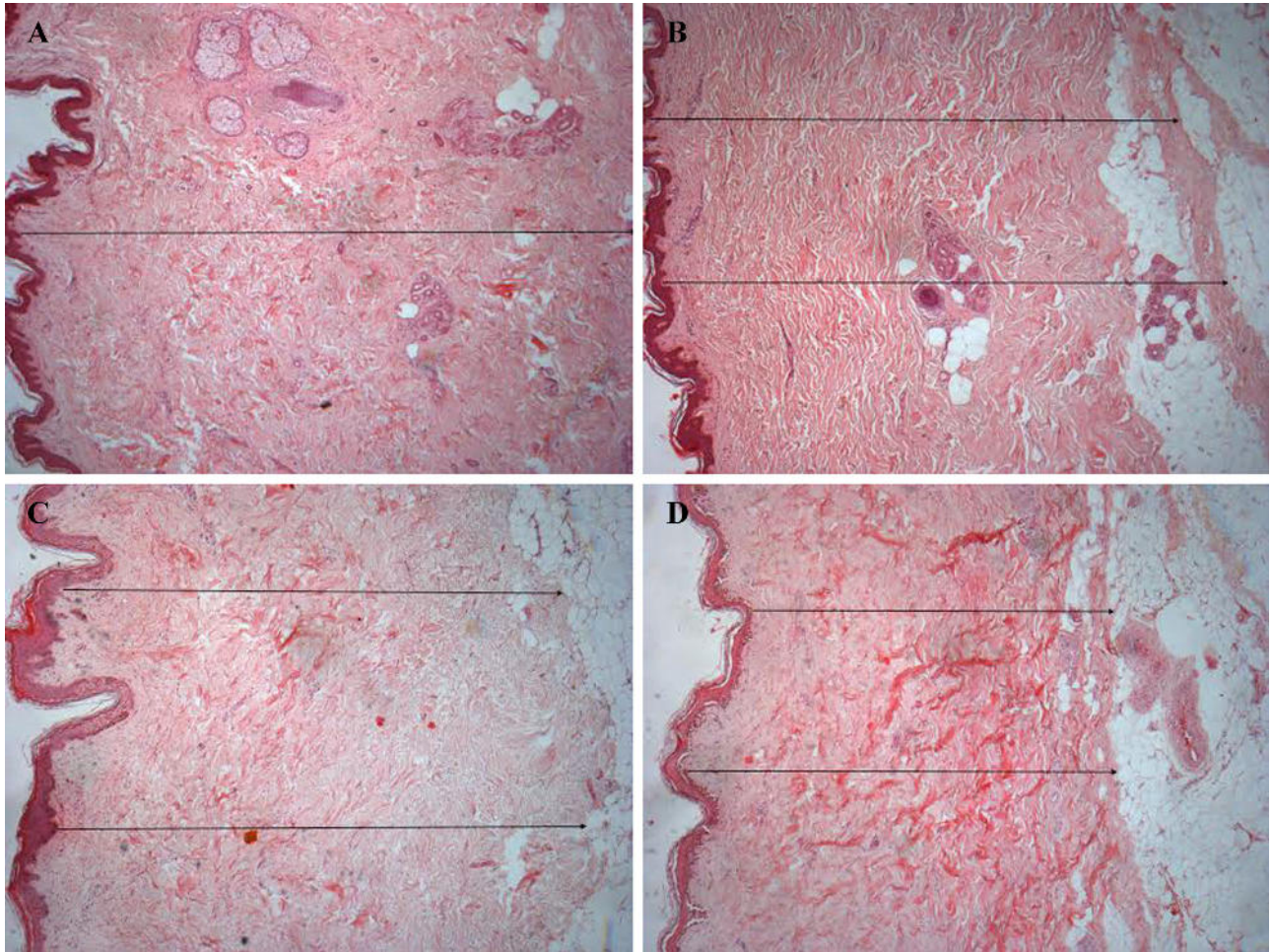


Fig. 7. Histology of the dermis in tissue culture. Tissue specimens, obtained during abdominoplasty, were cultured and processed for histologic analysis with Sirius red staining. Figures above (100 magnification) are from nontreated (control) skin (A), and skin treated with a series of six noninvasive RF treatments (B), on day 0 of tissue culture. Figures (C) and (D) represent nontreated (control) and treated skin, respectively, after 14 days in tissue culture. Note the reduction in thickness of the dermis, more compact collagen and reduction in elastosis following the series of RF treatments, and that the effects continue to improve over time (B,D). Figures above (100× magnification).

collagen resulted in a noticeably compacted, organized dermis. This synchronous dermal enhancement is an important effect, given that patients who undergo noninvasive fat reduction typically also seek skin tightening along with fat reduction. While other noninvasive devices have been able to achieve adipocyte destruction and fat layer reduction, this novel RF device is unique in its ability to simultaneously achieve long-term improvement in subcutaneous fat through apoptosis and skin tightening with a single technology. This represents a substantial improvement over currently available technologies.

Only mild and transient adverse events were noted during the series of treatments. Most of the adverse effects were related to the device's thermal mechanism of action and the mild electrical sensation of the high-voltage pulsing. Notably, no patients suffered thermal burns to the skin and there were no reports of cutaneous sensory changes or painful dysesthesia in any patients. Thus, the

device appears to be a safe and effective option for treating subcutaneous adipose tissue.

There are, of course, limitations to this study. First, the study examined only 24 subjects, which may limit the power of the results; however, the results were statistically significant with the number of subjects enrolled. Second, while the study demonstrated significant improvement immediately following the series of treatments, as well as 3 months after the completion of the series, it remains unknown whether this clinical improvement will be maintained over years. Third, the clinical parameters utilized in this study were conservative, which may have contributed to a less dramatic clinical improvement; recently, the authors have utilized higher temperature cut off values and higher intensity ultra-short pulse duration RF pulses, with associated greater clinical improvement, greater reduction in abdominal circumference, and increased reduction of adipose tissue weight.

Lastly, while the histologic and immunohistochemistry data shown in this study are very promising, they are based on a limited series of only three patients.

Nonetheless, this device represents a novel treatment option for patients seeking noninvasive fat reduction. With the incorporation of two types of RF treatments: (1) a basic RF pulse in the standard 1 MHz range for thermal heating, and (2) trains of ultra-short pulse duration, high-amplitude, high-voltage RF pulses to cause IRE, this device achieves significant reductions in abdominal circumference, subcutaneous fat layer thickness, and adipose tissue weight by inducing adipocyte apoptosis. In addition, this device also allows for remodeling and tightening of the existing collagen in the treatment area, and stimulates neocollagenesis. This combination of skin tightening and long-term subcutaneous adipose tissue reduction represents an ideal treatment option for noninvasive fat reduction. In the future, larger and longer-term studies may be necessary to further determine the efficacy of this device and to elucidate the optimal treatment protocols.

REFERENCES

- Podda M, Kaufmann R, Bergfeld D. Development, anatomy, and physiology of adipose tissue. In: Hanke CW, Sattler G, Sommer B, editors. *Textbook of liposuction*, 1st edition. London, UK: Informa; 2007. pp 13–20.
- Klein JA. The tumescent technique; anesthesia and modified liposuction technique. *Dermatol Clin* 1990;8(3):425–437.
- Rohrich RJ, Beran SJ, Kenkel JM, Adams WP Jr, DiSpaltro F. Extending the role of liposuction in body contouring with ultrasound-assisted liposuction. *Plast Reconstr Surg* 1998;101(4):1117–1119.
- Goldman A. Submental Nd:YAG laser assisted liposuction. *Lasers Surg Med* 2006;38(3):181–184.
- Prado A, Andrades P, Danilla S, Leniz P, Castillo P, Gaete F. A prospective, randomized, double-blind, controlled clinical trial comparing laser-assisted lipoplasty with suction assisted-lipoplasty. *Plast Reconstr Surg* 2006;118:1032–1045.
- Dibernardo BE. Randomized, blinded, split abdomen study evaluating skin shrinkage and skin tightening in laser-assisted liposuction versus liposuction control. *Aesth Surg J* 2010;30(4):593–602.
- Paul MD, Mulholland RS. A new approach for adipose tissue treatment and body contouring using radiofrequency-assisted liposuction. *Aesth Plast Surg* 2009;33(5):687–694.
- Paul MD, Blugerman G, Kreindel M, Mulholland RS. Three-dimensional radiofrequency tissue tightening: A proposed mechanism and applications for body contouring. *Aesth Plast Surg* 2011;35(1):87–95.
- Duncan DI. Improving outcomes in abdominal liposuction: Comparing skin contraction with radiofrequency assisted lipocontouring (RFAL) plus SAL to SAL alone. Present IMCAS Paris, January 2011.
- Mulholland RS, Paul MD, Chalfoun C. Non-invasive body contouring with radiofrequency, ultrasound, cryolysis, and low-level laser therapy. *Clin Plast Surg* 2011;38:503–520.
- Mulholland RS. Radio frequency energy for non-invasive and minimally invasive skin tightening. *Clin Plast Surg* 2011;38:437–448.
- Mulholland RS, Kreindel M. Non-Surgical body contouring: Introduction of a new non-invasive device for long-term localized fat reduction and cellulite improvement using controlled, suction coupled, radiofrequency heating and high voltage ultra-short electrical pulses. *J Clin Exp Dermatol Res* 2012;3(4):157–165.
- Boisnic S, Branchet-Gumila MC, Benslama L, Le Charpentier Y, Arnaud-Battandier J. Long term culture of normal skin to test the efficacy of a hydroxy acid-containing cream. *Eur J Dermatol* 1997;7(4):271–273.
- Chapman SJ, Walsh A, Beckett E, Vickers CFH. A fully differentiating epidermal model with extended viability: Development and partial characterization. *J Invest Dermatol* 1989;93:762–768.
- Kondo S, Hozumi Y, Aso K. Long-term organ culture of rabbit skin: Effect of EGF on epidermal structure in vitro. *J Invest Dermatol* 1990;95:397–402.
- Branchet-Gumila MC, Boisnic S, Le Charpentier Y, Nonotte I, Montastier C, Breton L. Neurogenic modifications induced by substance P in an organ culture of human skin. *Skin Pharmacol Applied Skin Physiol* 1999;12:211–220.
- Boisnic S, Branchet-Gumila MC, Le Charpentier Y, Segard C. Repair of UVA-induced elastic fiber and collagen by 0.05% retinaldehyde cream in an ex vivo human skin model. *Dermatology* 1999;199S:43–48.
- Boisnic S, Branchet-Gumila MC, Segard C. Inhibitory effect of Avene spring water on vasoactive intestinal peptide-induced inflammation in surviving human skin. *Int J Tissue React* 2001;XXII(4):71–76.
- Mahé YF, Boisnic S, Béranger JY, Branchet-Gumila MC, Renault B, Breton L. Eyelid skin explants under neuro-inflammatory stress: Synergic protection by escine and dextran sulfate. *J Appl Cosmetol* 2001;19:1–10.
- Boisnic S, Branchet-Gumila MC, Coutanceau C. Inhibitory effect of oatmeal extract oligomer on vasoactive intestinal peptide-induced inflammation in surviving human skin. *Int J Tissue React* 2003;25:41–46.
- Boisnic S, Licu D, Ben Salma L, Branchet-Gumila MC, Szpirglas H, Dupuy P. Topical retinaldehyde treatment in oral lichen planus and leukoplakia. *Inter J Tissue React* 2002;24(4):123–130.
- Davalos R, Mir LM, Ribinsky B. Tissue ablation with irreversible electroporation. *Ann Biomed Eng* 2005;33:223–231.
- Schoenbach KH, Hargrave B, Joshi RP, Kolb JF, Nuccitelli R, Osgood C, Pakhomov A, Stacey M, Swanson RJ, White JA, Xiao S, Zhang J, Beebe SJ, Blackmore PF, Buescher ES. Bioelectric effects of intense nanosecond pulses. *IEEE Trans Dielectr Electr Insul* 2007;14:1088–1109.
- Schoenbach KH, Xiao S, Joshi RP, Camp JT, Heeren T, Kolb JF, Beebe SJ. The effect of intense sub-nanosecond electrical pulses on biological cells. *IEEE Trans Plasma Sci* 2008;36:414–422.
- Altunc S. Subnanosecond pulsed-power generated electric fields for cancer treatment. *IEEE Nucl Plasma Sci Soc News* 2009; 34–37.
- Garner AL, Chen G, Chen N, Sridhara V, Kolb JF, Swanson RJ, Beebe SJ, Joshi RP, Schoenbach KH. Ultra-short electric pulse induced changes in cellular dielectric properties. *Biochem Biophys Res Commun* 2007;362:139–144.
- Rubinsky B, Onik G, Mikus P. Irreversible electroporation: A new ablation modality—Clinical implications. *Technol Cancer Res Treat* 2007;6:1–12.
- Rubinsky B. Irreversible electroporation in medicine. *Technol Cancer Res Treat* 2007;6:255–259.
- Miller L, Leor J, Rubinsky B. Cancer cells ablation with irreversible electroporation. *Technol Cancer Res Treat* 2005;4:1–7.
- Onik G, Rubinsky B, Mikus P. Irreversible electroporation: Implications for prostate ablation. *Technol Cancer Res Treat* 2007;6:1–6.
- Maor E, Ivorra A, Leor J. The effect of irreversible electroporation on blood vessels. *Technol Cancer Res Treat* 2007;6:307–312.